

LONDON
SCHOOL of
HYGIENE
& TROPICAL
MEDICINE



Asayag, CR; Garay, CR; Sanchez, GM; Angeles, CC; Baca, CJ; Evans, C; Yori, PP; Kosek, M (2008) Eight year old with fever, hepatomegaly, and positive thick smear. *The American journal of tropical medicine and hygiene*, 79 (4). p. 473. ISSN 0002-9637

Downloaded from: <http://researchonline.lshtm.ac.uk/5226/>

DOI:

Usage Guidelines

Please refer to usage guidelines at <http://researchonline.lshtm.ac.uk/policies.html> or alternatively contact researchonline@lshtm.ac.uk.

Available under license: <http://creativecommons.org/licenses/by/2.5/>

Images in Clinical Tropical Medicine

Eight Year Old with Fever, Hepatomegaly, and Positive Thick Smear

Cesar Ramal Asayag, Camilo Ruiz Garay, Graciela Meza Sanchez, Cristiam Carey Angeles, Cesar Jara Baca, Carlton Evans, Pablo Peñataro Yori, and Margaret Kosek*

Hospital Regional de Loreto, Iquitos, Peru; Epidemiology Division, Regional Ministry of Health of Loreto, Iquitos, Peru; A. B. Prisma, Lima, Peru; Department of International Health, Johns Hopkins School of Public Health, Baltimore, Maryland

An 8-year-old girl from the rural eastern Amazon department of Loreto presented to her local health post with a 1-week history of fever, headache, and poorly localized abdominal discomfort. At the health post, the child had a temperature of 39°C. A thick smear was obtained, and the patient was started on chloroquine after parasites were observed on the thick smear. The smear was referred to a regional diagnostic center for further evaluation. There the smear was found to be negative for *Plasmodium* species but positive for *Trypanosoma cruzi* with 0.5 parasites/hpf (Figure 1).

After the identification of *T. cruzi* on the thick smear, the patient was transferred to a regional hospital to facilitate follow-up. On arrival, the patient was febrile, but otherwise well with no focal neurologic signs, lymphadenopathy, or evidence of cardiac insufficiency. Her physical exam was notable only for mild non-tender hepatomegaly. Her EKG was normal. Her enzyme-linked immunosorbent assay (Chagatek) was positive, and her immunofluorescent assay titer was 1:32. She was able to recall seeing a “chinche” (local term for triatomines) near her home and being bitten on the foot by one 2 weeks before presentation. She had mild swelling at the site of the bite for 3 days. She had never traveled outside the small region surrounding her village. She received nifurtimox without significant complications.

In Peru, the principal area of transmission of Chagas disease is the Southern Andes. Although a sylvatic cycle is well recognized in both Brazil and Ecuador,^{1,2} this is the first case of documented slide-positive acute Chagas disease in Loreto, and this has initiated an outbreak study in the region of this case. Entomologic work in Loreto has documented the presence of competent vectors.³ Because disease is likely to be sporadic in this as in other parts of the Amazon where the vector is associated with palm trees rather than being located in homes, it is important that both clinicians and parasitologists in malaria programs in the region are correctly able to identify *T. cruzi* on thick smears. Manifestations of acute Chagas infection are highly variable, but most are asymptomatic, and even symptomatic cases are likely to present with a poorly differentiated febrile illness. A thick smear is available in most of the Amazon where malaria is common and will likely be obtained for malaria, as in this case. It is important

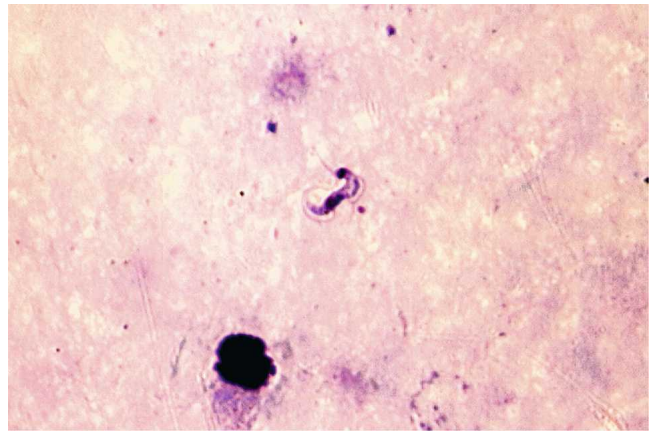


FIGURE 1. Patient's thick smear. This figure appears in color at www.ajtmh.org.

that technicians are able to correctly identify trypanosomes, as well as *Plasmodium* spp., to be able to detect cases of Chagas and target appropriate communities for disease interventions.

Received February 18, 2008. Accepted for publication June 27, 2008.

Authors' addresses: Cesar Ramal Asayag, Camilo Ruiz Garay, Graciela Meza Sanchez, and Cesar Jara Baca, Hospital Regional de Loreto, Av 28 de Julio s/n, Punchana, Iquitos, Peru. Cristiam Carey Angeles, Office of Epidemiology, Regional Department of Health of Loreto-DISA, Av 28 de Julio s/n, Punchana, Iquitos, Peru. Carlton Evans, A. B. Prisma, Lima, Peru. Pablo P. Yori and Margaret Kosek, Department of International Health, Johns Hopkins University School of Public Health, 615 N. Wolfe St. w5515, Baltimore, MD 21205.

REFERENCES

1. Aguilar HM, Abad-Franch F, Dias JC, Junqueira AC, Coura JR, 2007. Chagas disease in the Amazon region. *Mem Inst Oswaldo Cruz* 102 (Suppl 1): 47–56.
2. Chico M, Sandoval C, Guevara A, Calvopina M, Cooper PJ, Reed SG, Guderian RH, 1997. Chagas disease in Ecuador: evidence for disease transmission in an Indigenous population in the Amazon region. *Mem Inst Oswaldo Cruz* 92: 317–320.
3. Cuba CA, Abad-Franch F, Roldan RJ, Vargas VF, Pollack VL, Miles MA, 2002. The triatomines of northern Peru, with emphasis on the ecology and infection by trypanosomes of *Rhodnius ecuadoriensis* (Triatominae). *Mem Inst Oswaldo Cruz* 97: 175–183.

* Address correspondence to Margaret Kosek, Department of International Health, Johns Hopkins University School of Public Health, 615 N. Wolfe St. w5515, Baltimore, MD 21205. E-mail: mkosek@jhsph.edu